Utilidad de la Cirugía Mínimamente Invasiva en la Urología

Silvia Russo (Supervisora),

Maura Balbi, Yanina Sosa, Paula Ortega y Vanina Bonassin (Asistentes),

Christian Patiño, Estaban Cordero y Federico Larcade, Fernando P. Secin

Sección Urología CEMIC

Ausencia de conflicto de interés con la Industria

Objetivos

- Describir la Utilidad de la Cirugía laparoscópica en la Urología
- Ventajas y desventajas
- Perspectivas Futuras

Vía Urinaria Superior

- Nefrectomía Radical
- Nefrectomía Parcial
- Nefroureterectomía
- Ureterolisis
- Ureterolitectomía
- Plástica de la unión pieloureteral

Vía Urinaria Inferior

- Prostatectomía Radical
- Cistoprostatectomía radical
- Cistolitectomía
- Resección de divertículo vesical
- Linfadenectomía pelviana
- Reparación de fístulas entero vaginales o entero urinarias

Ventajas de la cirugía mínimamente invasiva

- Menor sangrado
- Rápida recuperación postoperatoria
- Menor requerimiento de analgésicos
- Alta hospitalaria precoz
- Reincorporación precoz a la vida diaria
- Menor impacto psicológico sobre el paciente y menor costo social

Desventajas de la cirugía mínimamente invasiva

- Se necesita entrenamiento individual y de equipo

Magnificación de la visualización

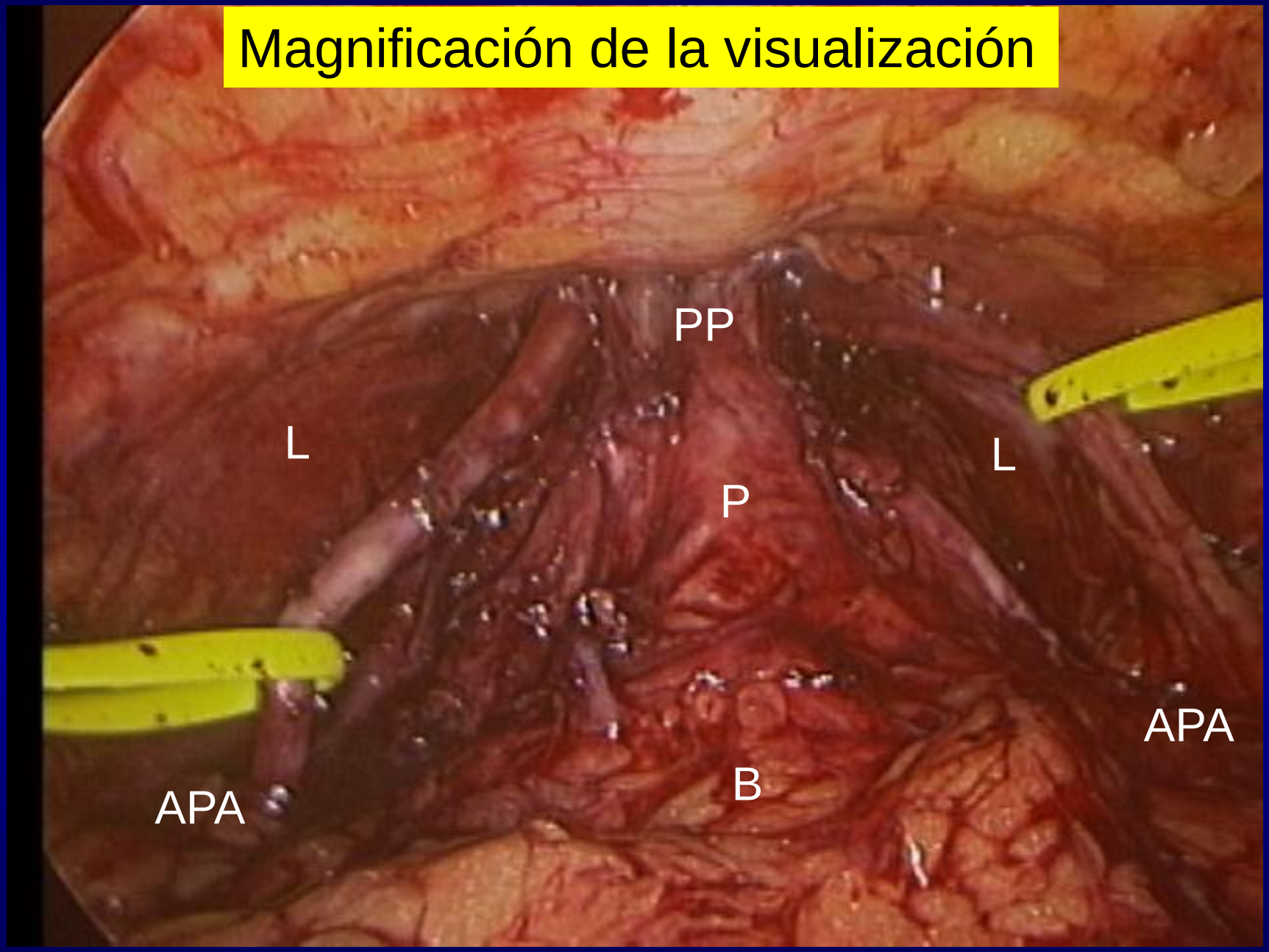

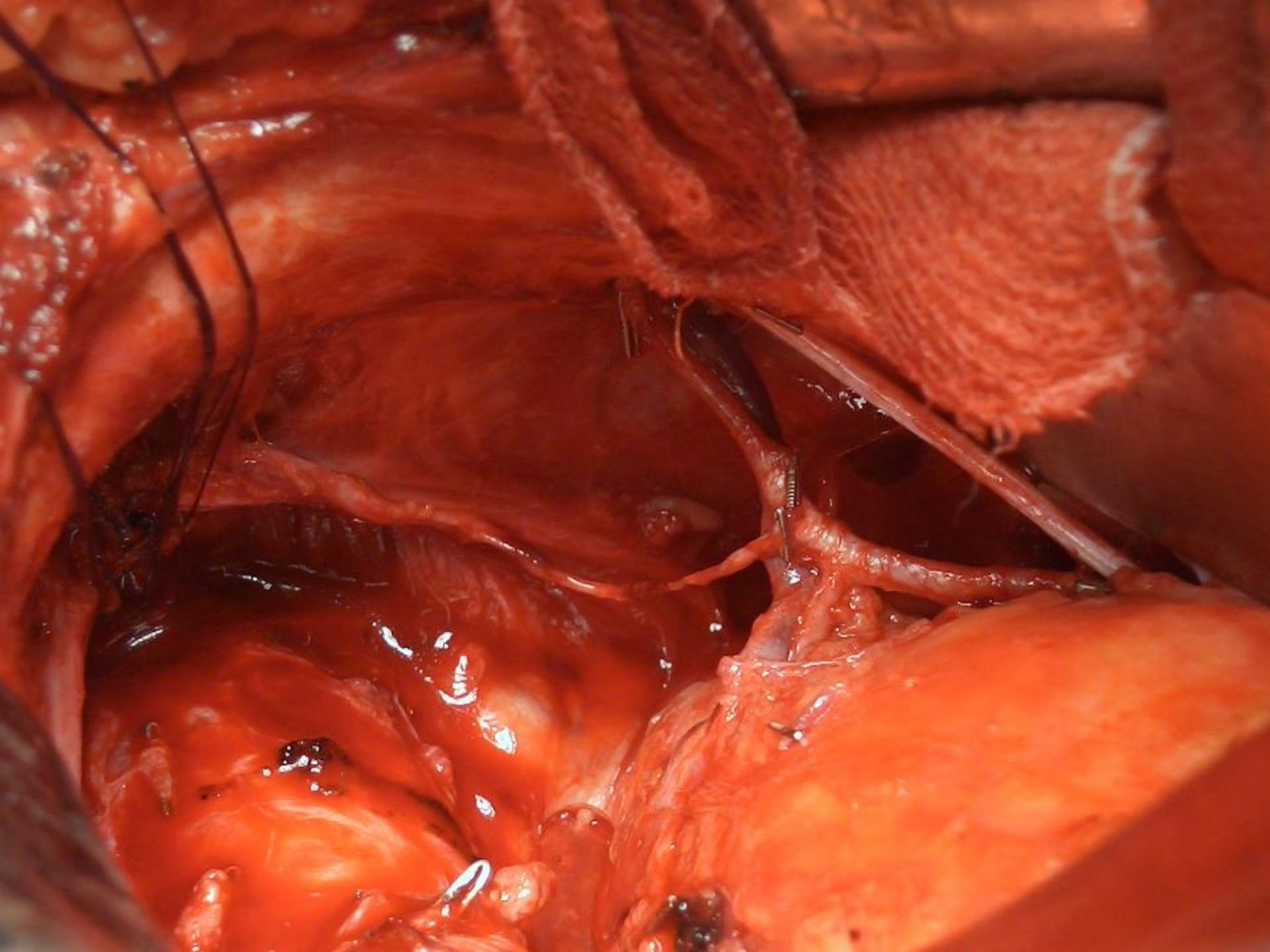

Prostatectomía Laparoscopica

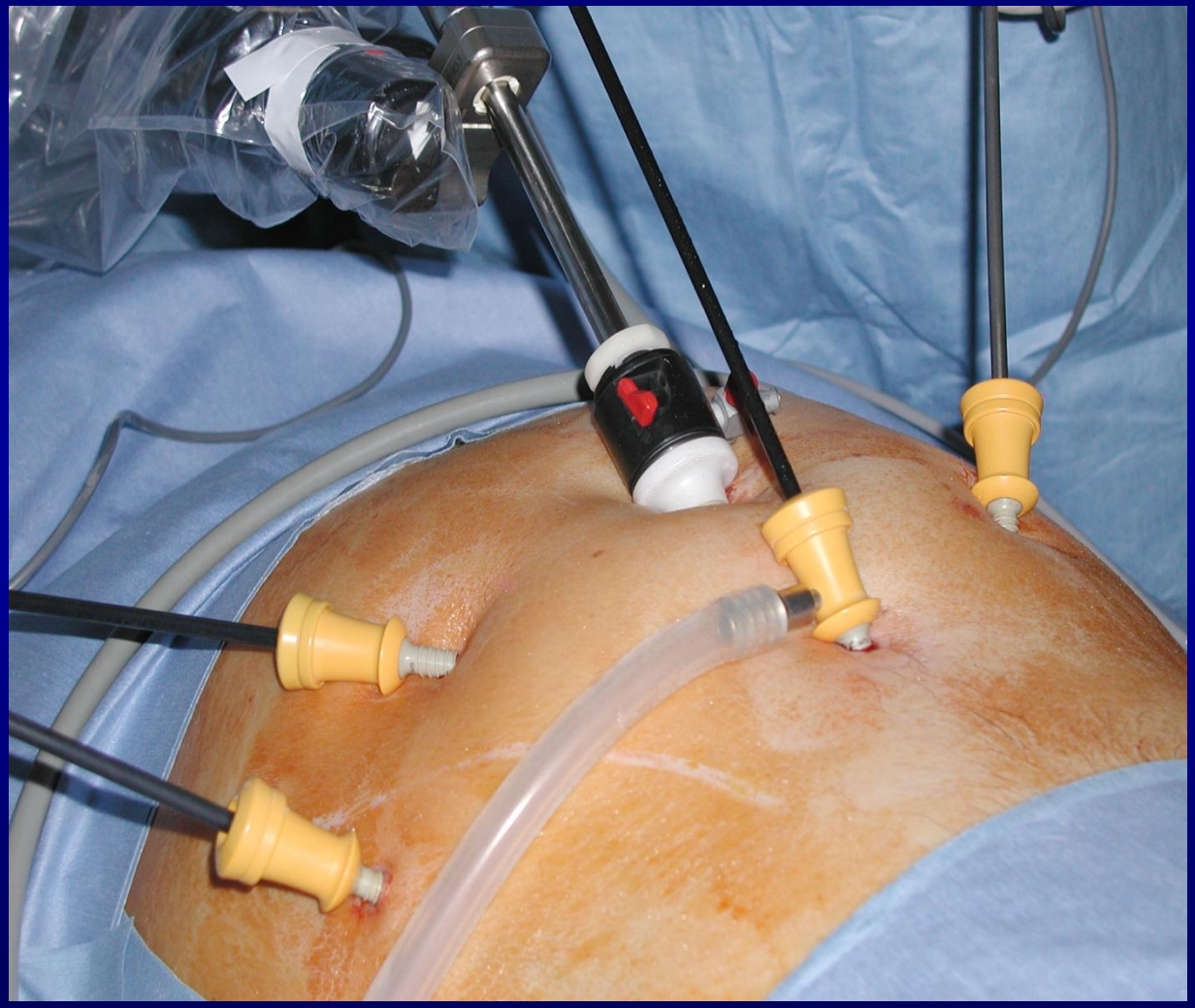

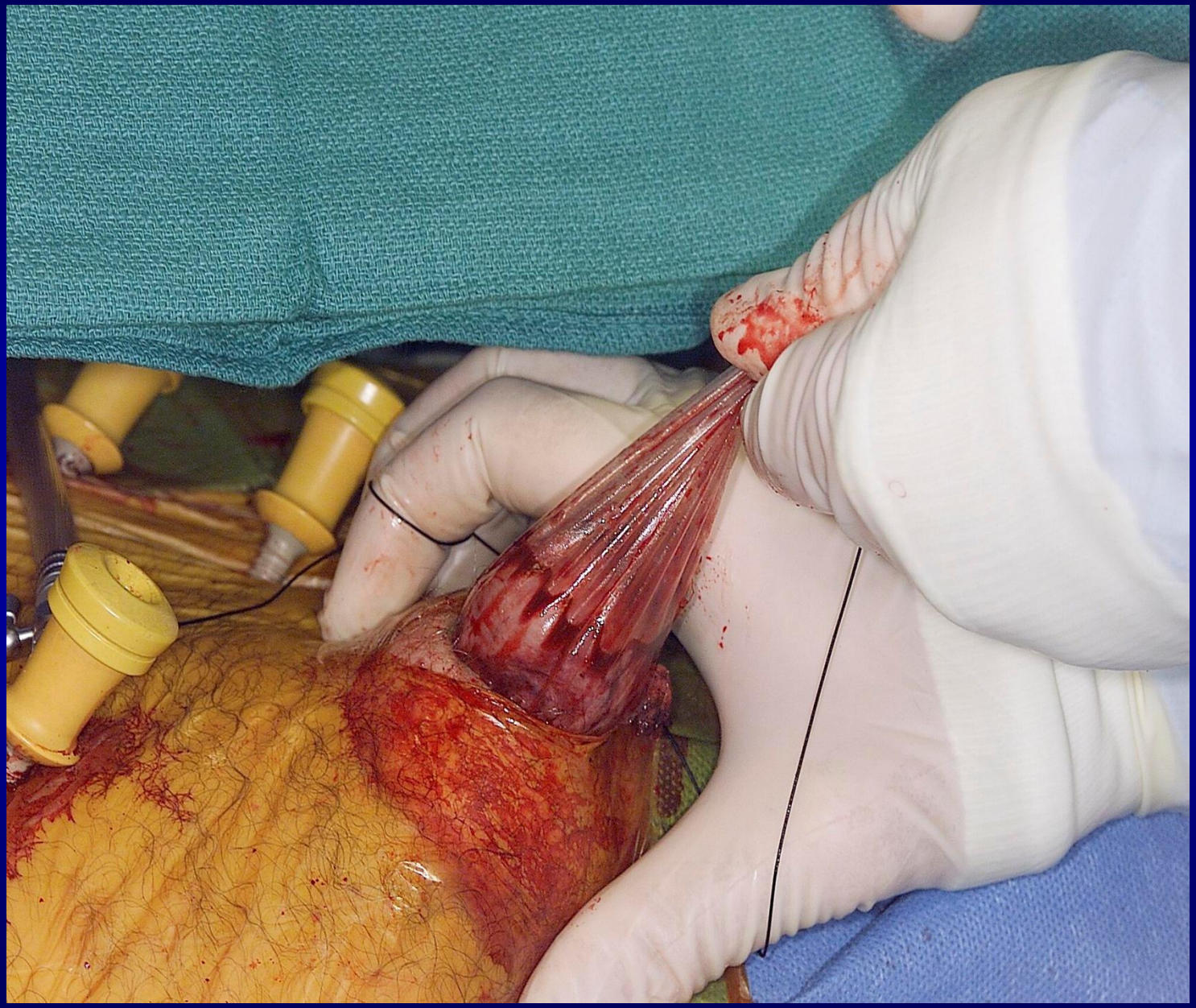

Prostatectomía Laparoscópica en paciente obstruido

- Varón de 53 años.
- PSA: 5 ng / ml
- Próstata de 80 gramos
- Síntomas obstructivos
- 4/14 Biopsias positivas

Gleason 3+3

- Sangrado 600 cc.

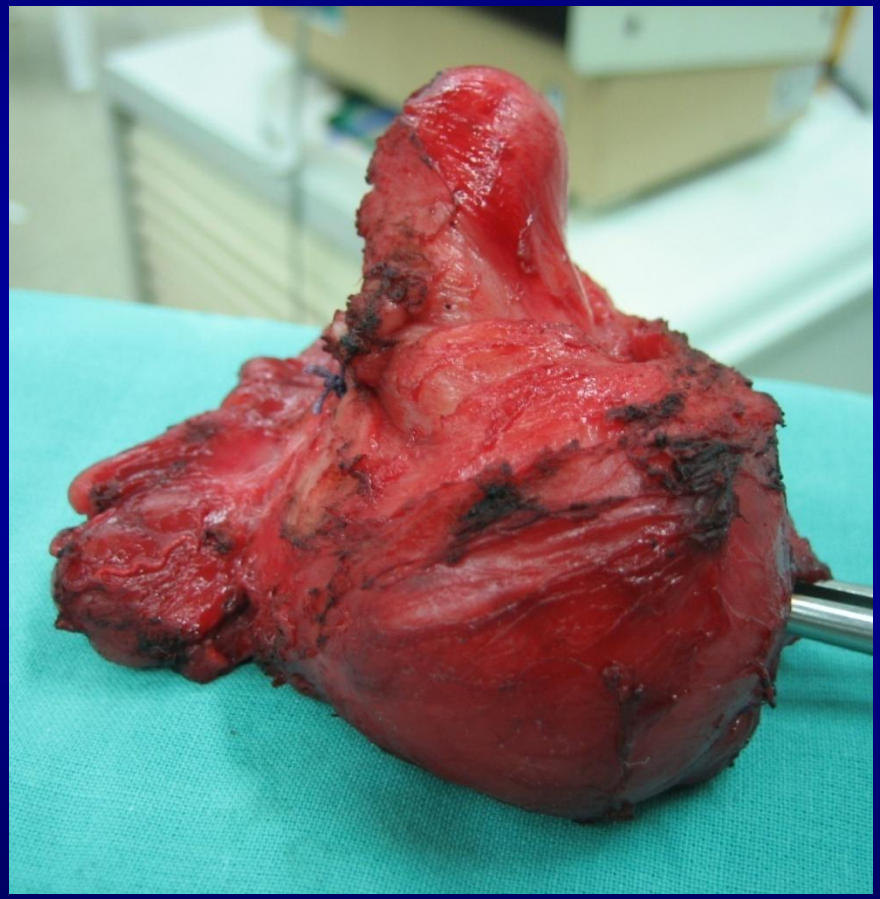

Prostatectomía a Cielo Abierto

- Médico de 64 años.
- PSA: 12.5
- Próstata de 100 gramos por Ecografía
- Síntomas Urinarios
- 2/14 Biopsias positivas Gleason 3+3 ápex izquierdo
- Sangrado 600 cc. Autotransfusión 1 Unidad.
- Lumbalgia x el flex

0022-5347/00/1644-1153/0
THE JOURNAL OF UROLOGY®

Vol. 164, 1153–1159 October 2000
Printed in U.S.A.

LAPAROSCOPIC VERSUS OPEN RADICAL NEPHRECTOMY: A 9-YEAR EXPERIENCE

MATTHEW D. DUNN, ANDREW J. PORTIS, ARIEH L. SHALHAV, ABDELHAMID M. ELBAHNASY, CINDY HEIDORN, ELSPETH M. McDOUGALL* AND RALPH V. CLAYMAN†,‡

From the Departments of Surgery, Urology and Radiology, Mallinckrodt Institute of Radiology, Washington University School of Medicine, St. Louis, Missouri, and Department of Urology, Tanta University, Tanta, Egypt

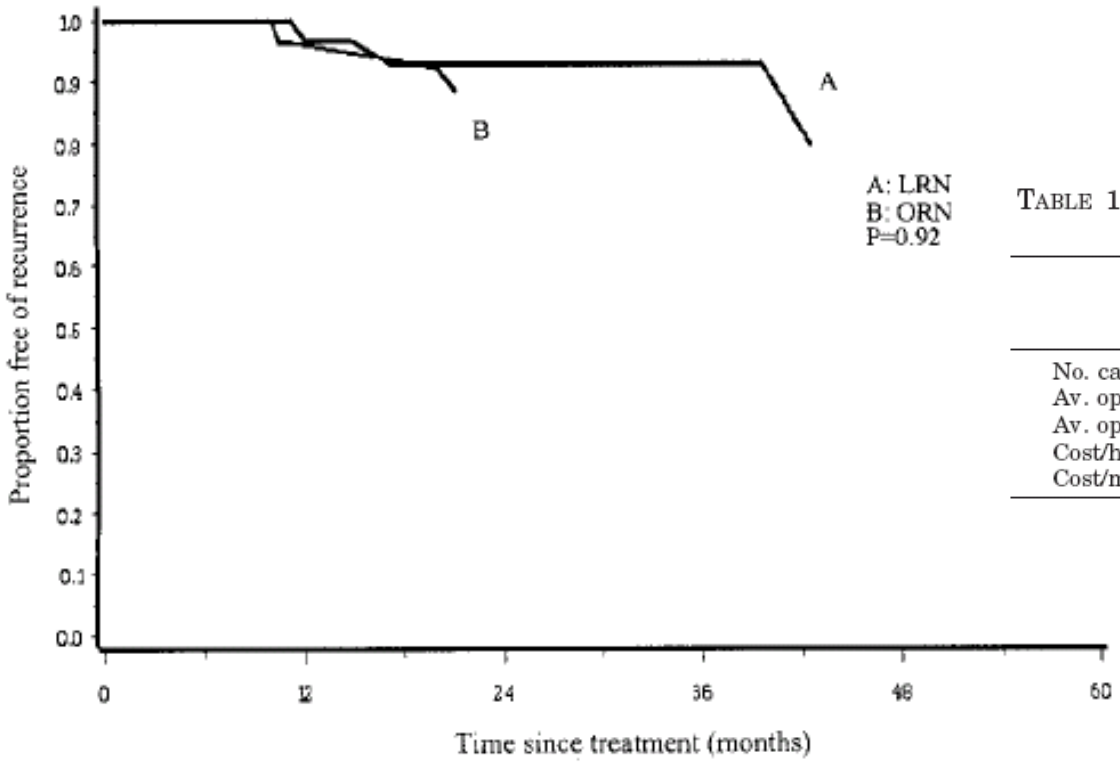

TABLE 11. *Cost comparison of 5 most recent laparoscopic and open radical nephrectomy cases*

	Laparoscopic Radical Nephrectomy	Open Radical Nephrectomy
No. cases	5	5
Av. operating cost	$6,332.60	$4,431.40
Av. operating time (hrs.)	3.53	2.75
Cost/hr.	$1,793.94	$1,611.42
Cost/min.	$ 30	$ 27

0022-5347/00/1644-1153/0
THE JOURNAL OF UROLOGY®

Vol. 164, 1153–1159 October 2000
Printed in U.S.A.

LAPAROSCOPIC VERSUS OPEN RADICAL NEPHRECTOMY: A 9-YEAR EXPERIENCE

MATTHEW D. DUNN, ANDREW J. PORTIS, ARIEH L. SHALHAV, ABDELHAMID M. ELBAHNASY, CINDY HEIDORN, ELSPETH M. McDOUGALL* AND RALPH V. CLAYMAN†,‡

Mallinckrodt Institute of Radiology, Washington University School of
rtment of Urology, Tanta University, Tanta, Egypt

TABLE 3. *Laparoscopy group: complications*

No.	Complication
1	Mild congestive heart failure, early postop.
2	1 unit transfusion early postop., bilat. pleural effusion managed medically, retroperitoneal hematoma, 6 cm., ileus 3 days, late congestive heart failure, atrial fibrillation 3 wks. postop., hypertension, 3 rehospitalizations for aforementioned, gastrointestinal upset, urinary tract infection
4	Atelectasis requiring intensive respiratory treatment
5	Paroxysmal atrial fibrillation late postop. after discharge from hospital
6	Sciatic and sural nerve dysfunction 3 mos.
9	Groin pain and numbness 4 wks.
11	Ileus 3 days, tachycardia
13*	Converted to open, thoracotomy, estimated blood loss 1,500 cc., difficult dissection
17	Incisional hernia
24	Fever, atelectasis
25	Urinary retention
32	Skin burn at lt. hip
33*	Superior mesenteric artery ligation, atrial fibrillation and myocardial infarction early postop., 1 unit transfusion intraop., 4 units transfusion postop.
35	Subdiaphragmatic hematoma (late diagnosis)
36	Hemorrhage from renal vein (minor, estimated blood loss 200 cc., no transfusion) Numbness on rt. side that resolved at 1-yr. followup
37	LapSac torn at edge
38	Pleural effusion, delayed extubation, ileus, hemorrhage from renal vein (estimated blood loss 200 cc., no transfusion)
39	Malfunction hemodialysis catheter
40	Early postop. mild congestive heart failure, 1 unit transfusion
46	Temperature 38.4C 1 day postop.
49	Small hematoma lt. upper quadrant 10-mm. port
50	Pure motor weakness rt. forearm that resolved in 8 wks.
53	Low grade fever 1 day postop. (38.3C), small venous injury at insertion rt. gonadal vein to vena cava repaired laparoscopically

Listed in the order in which nephrectomy was performed.
* Major complications.

TABLE 7. *Open nephrectomy: complications*

Pt. No.	Complication
1	Aortic or caval injury, estimated blood loss 500 cc., no transfusion
2	Pneumonthorax requiring postop. chest tube placement
3*	Superior mesenteric artery injury requiring reanastomosis, hemorrhage from renal artery, estimated blood loss 2000 cc, 3 units intraop. transfusion
9	Fever 38C 2 days
10	Pneumothorax requiring postop. chest tube
12	Intraop. bigeminy
13	Fever 38.5C 2 days, nasogastric tube replaced for ileus
14	Persistent incisional pain
15*	Intraop. large bowel injury, colon diverticular repair
17	1 Unit transfusion early postop.
18	Unspecified venous hemorrhage, estimated blood loss 800 cc, 1 unit intraop. transfusion
20	Persistent incisional pain
25*	Pulmonary embolism, 4 units transfusion intraop. (estimated blood loss 3,000 cc) hernia late
26	Unspecified venous hemorrhage, estimated blood loss 500 cc, no transfusion
29	Fever 38.5C for 2 days
30*	Large retroperitoneal hematoma requiring reexploration, pt. reintubated postop., 4 units postop. transfusion, creatinine increased to 3.2 mg./dl. postop., has end stage renal disease
31	Fever 38.6C 2 days
33	Wound infection, incisional pain 8 mos., numbness at incision site

Listed in order in which nephrectomy was performed.
* Major complications.


mm 1 2 3 4 5 6 7 8 9 10
1 Pulgada 2
INOX 3 4

Nefrectomía Radical Lap.

- Mujer de 30 a.
- IRC en Hemodialisis
- Proteinuria sintomatica
- Nefrectomía radical laparoscopica
- Sangrado 30 cc.
- Alta al 2º día

0022-5347/01/1653-0766/0
THE JOURNAL OF UROLOGY®

Vol. 165, 766–769, March 2001
Printed in U.S.A.

LAPAROSCOPIC LIVE DONOR NEPHRECTOMY: A COMPARISON WITH THE CONVENTIONAL OPEN APPROACH

SCOTT L. BROWN, THOMAS R. BIEHL, MATHEW C. RAWLINS AND THOMAS R. HEFTY

From the Department of Urology and Renal Transplantation and the Department of Surgery, Virginia Mason Medical Center, Seattle, Washington

TABLE 1. *Laparoscopic versus open donor nephrectomy*

	Laparoscopic	Open	p Value
No. pts.	50	50	
Surgery dates	10/98–5/00	2/98–3/00	
Mean donor age	38.6	40.9	0.270
Donor sex (M/F)	23/27	30/20	0.229
Mean No. HLA mismatches	2.37	2.73	0.230
Mean followup (days)	109	331	0.0001
Mean operative time (mins.)	234	208	0.0068
Mean blood loss (ml.)	114	193	0.0001
Mean hospital stay (days)	3.5	4.7	0.0001
Mean mg./dl. creatinine (postop. day):			
−1	8.58	8.58	0.980
1	3.94	3.94	0.990
5	1.46	1.48	0.710
30	1.95	1.53	0.660

TABLE 2. *Etiology of graft failure and months after transplantation in laparoscopic and open nephrectomy groups*

Etiology (No. pts.)	Mos. After Transplantation
Laparoscopic (4):	
Infection	3
Acute rejection	2
Chronic rejection	4
Death from myocardial infarction	2
Open (3):	
Uremia	7
Death from myocardial infarction	18
Death from stroke	1

¿Es la Robótica el futuro de la cirugía?

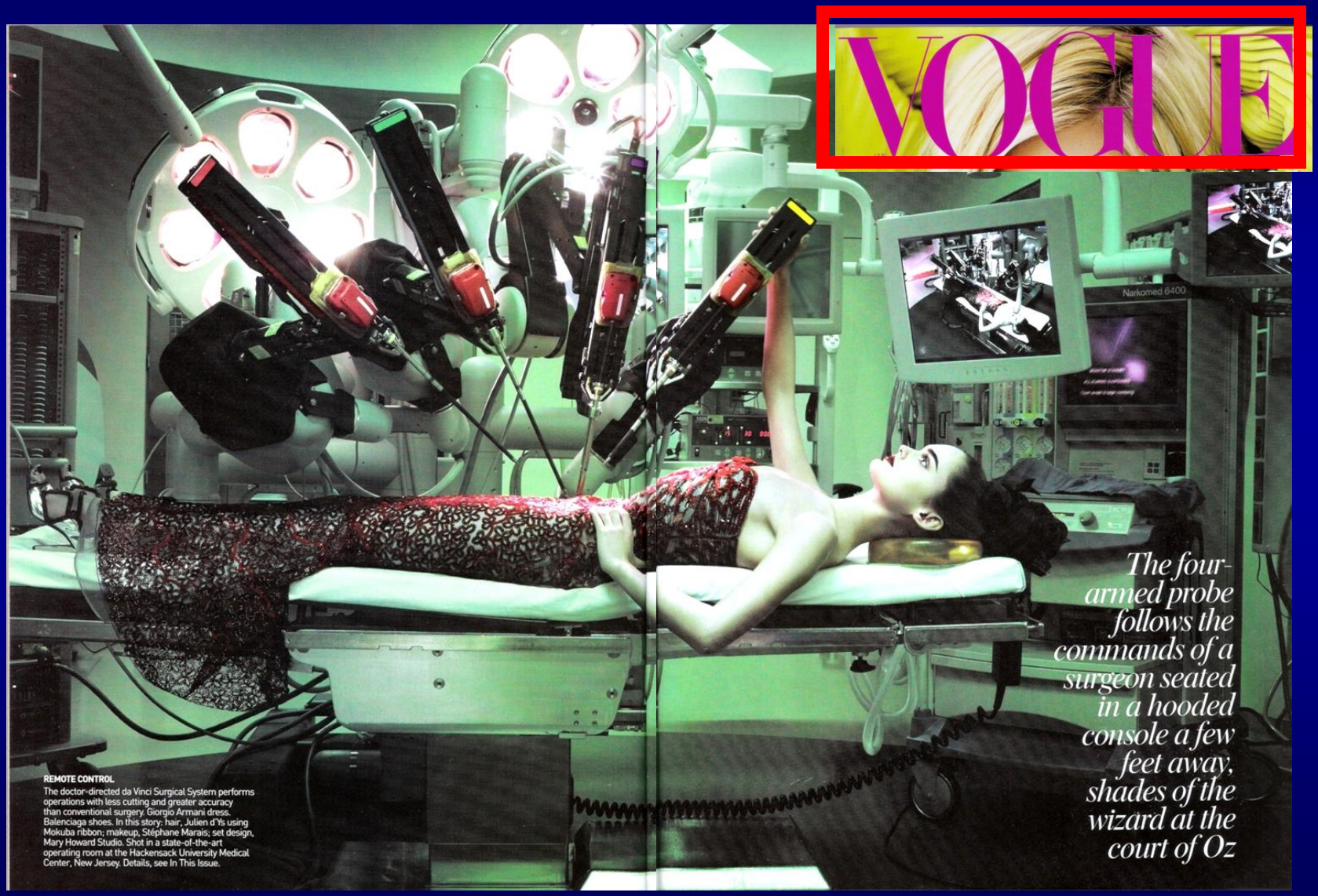

Sistemas “Maestro-Esclavo”

Sistemas “Maestro-Esclavo”

- Da Vinci (2001) (Intuitive Surgical)

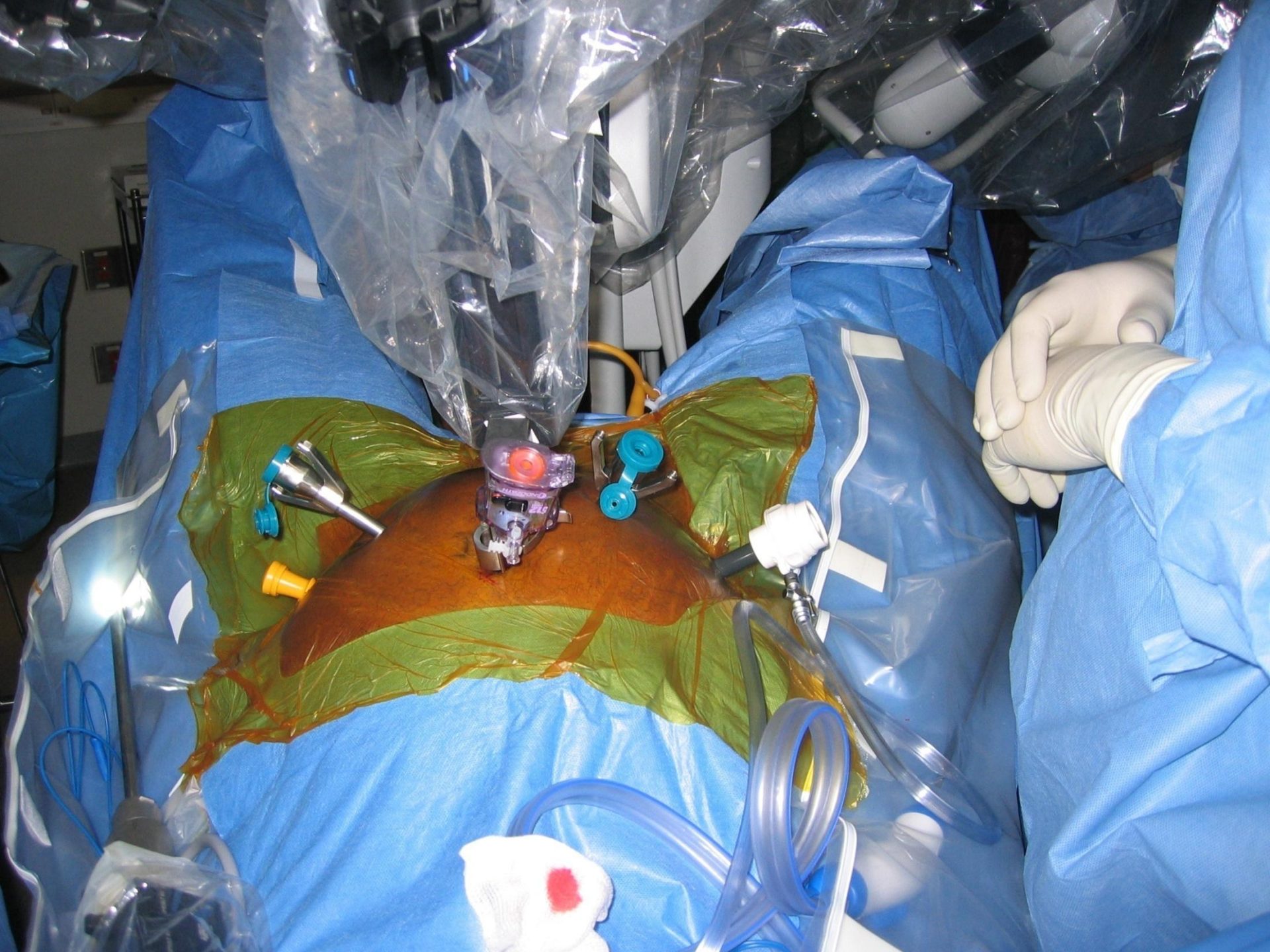

Cirugía Laparoscópica Pura

¿Cuál es su principal problema?

“ Los procedimientos laparoscópicos avanzados (en especial lo que incluyen sutura) requieren de mucho entrenamiento y tiene una curva de aprendizaje muy prolongada”

Dificultades para el Cirujano

- Amplificación de los movimientos
- Instrumentos rígidos
- Postura menos ergonómica
- Larga curva de aprendizaje
- Tiempos quirúrgicos prolongados

La robótica ha llegado para aportar algunas SOLUCIONES

- Visión tridimensional
- Magnificación
- Mas grados de libertad
- Movimientos naturales, intuitivos, a escala y sin temblor
- Ergonomía para el cirujano


fail

Cuidado del Material

Trabajo de EQUIPO

Agradecimiento

- SAU
- Lic. Silvia Russo, jefa de Instrumentadoras
- Paula Ortega
- Maura Balbi
- Equipo de Instrumentadoras de CEMIC:

  Stella, Yanina, Vanina, Romina, Natalia, Mercedes, Alicia.

Las que no estan mas: Adriana, Eva, Julieta, Mary Oberti.


MEGATONE


ARDOZO